

CHOLANGIOMA IN A WILD-CAUGHT SHEEPSHEAD MINNOW (*CYPRINODON VARIEGATUS*) FROM THE NORTHERN GULF OF MEXICO

Lee A. Courtney

U.S. Environmental Protection Agency, National Health and Environmental Effects
Research Laboratory, Gulf Ecology Division, Center for Marine and Estuarine Disease
Research, 1 Sabine Island Drive, Gulf Breeze, Florida 32561-5299, USA

ABSTRACT A single case of a cholangioma occurred in the liver of a wild-caught sheepshead minnow (*Cyprinodon variegatus*). This is the first biliary neoplasm and second case of a hepatic neoplasm reported from a wild-caught specimen of this species. The findings further demonstrate the susceptibility of the sheepshead minnow to neoplasm development and add support to its selection as a subject for field monitoring of carcinogenic exposure.

INTRODUCTION

The use of fish species as sentinels of carcinogen exposure in the aquatic environment is a significant tool for identifying compromised ecosystems. Many important attributes of fish sentinels make their use in experimental carcinogenicity testing and field monitoring both efficacious and advantageous (Dawe and Couch 1984). One important consideration, particularly regarding field monitoring for environmental carcinogens, is the relatively low rate of spontaneous neoplasm development in fishes. Furthermore, a high correlation has been demonstrated between environmental contamination and most reported epizootics of hepatic neoplasms in fishes (Harshbarger and Clark 1990; Baumann 1992). These factors emphasize the importance of hepatic neoplasms in non-treated fishes and, particularly, in wild populations.

The sheepshead minnow, *Cyprinodon variegatus* Lacépède, has demonstrated its susceptibility to chemically-induced hepatic neoplasm development in various carcinogen studies (e.g., Couch and Courtney 1987; Hawkins et al. 1991). It is a small estuarine teleost with a limited home range inhabiting coastal waters from New England to northern South America. To date, the only reports of spontaneous neoplasm development in sheepshead minnows involve thyroid adenomas in aquarium-held specimens (Nigrelli 1952; Lightner and Meineke 1979) and a single case of hepatocellular adenoma in a wild-caught specimen (Oliveira et al. 1994). This paper describes a cholangioma found in a wild-caught sheepshead minnow from an ongoing study on P-glycoprotein expression in tissues of teleost fishes and the possible role of xenobiotics in the disruption of its function as a transepithelial efflux pump (Hemmer and Courtney, personal communication).

MATERIALS AND METHODS

Approximately 30 sheepshead minnows (*Cyprinodon variegatus*) were collected in a lagoon off Santa Rosa Sound on the north shore of Santa Rosa Island, Florida, approximately 2 kilometers east of the Navarre Beach bridge. Specimens were collected by seine net, cut ventrally to open the visceral mass and immersed in Bouin's solution in the field. They were fixed for 48 hours, washed in running water for six hours and stored in 70% ethanol at room temperature. Liver, intestine and kidney tissues were dissected from 10 of the preserved specimens, dehydrated in a graded ethanol series, cleared in xylene and embedded in paraffin. Sections were cut on a rotary microtome at 5 μ m, mounted on poly-L-lysine coated slides and air dried. Initial sections were processed for immunohistochemical labeling with four different P-glycoprotein antibodies [monoclonals C219, C494 and JSB-1; polyclonal mdr(Ab-1)] and counterstained with Mayer's hematoxylin (Hemmer et al. 1995). Additional sections were stained with Harris' hematoxylin and eosin.

RESULTS AND DISCUSSION

During evaluation of samples for P-glycoprotein antibody reactions, a neoplastic lesion was found in the liver of one specimen, an adult female (4.5 gm wet weight; 50 mm SL). The lesion was a well-circumscribed cholangioma approximately 750 x 960 μ m in greatest dimension. It occupied ~2.5% of the liver area in the plane of section examined and was situated at the periphery of the liver (Figure 1). The lesion had regular, well-defined borders with no invasion into surrounding parenchyma. It consisted of numerous well-formed bile ducts possessing normal-appearing cuboidal epithelium within a minimal

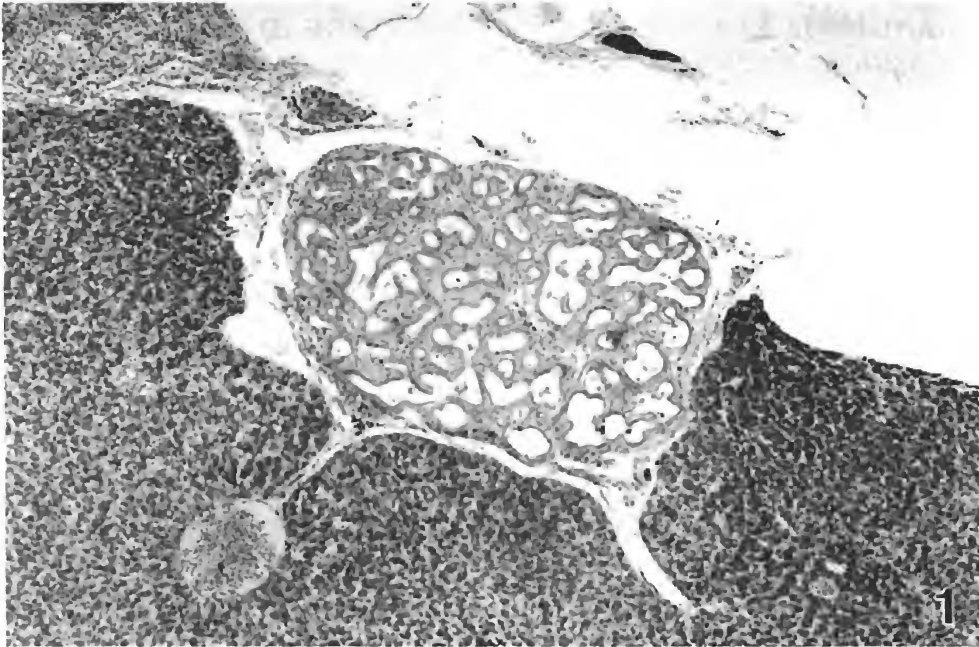


Figure 1. Low power magnification showing well-circumscribed cholangioma located at periphery of liver of a sheephead minnow (*Cyprinodon variegatus*). (H&E; 76x).

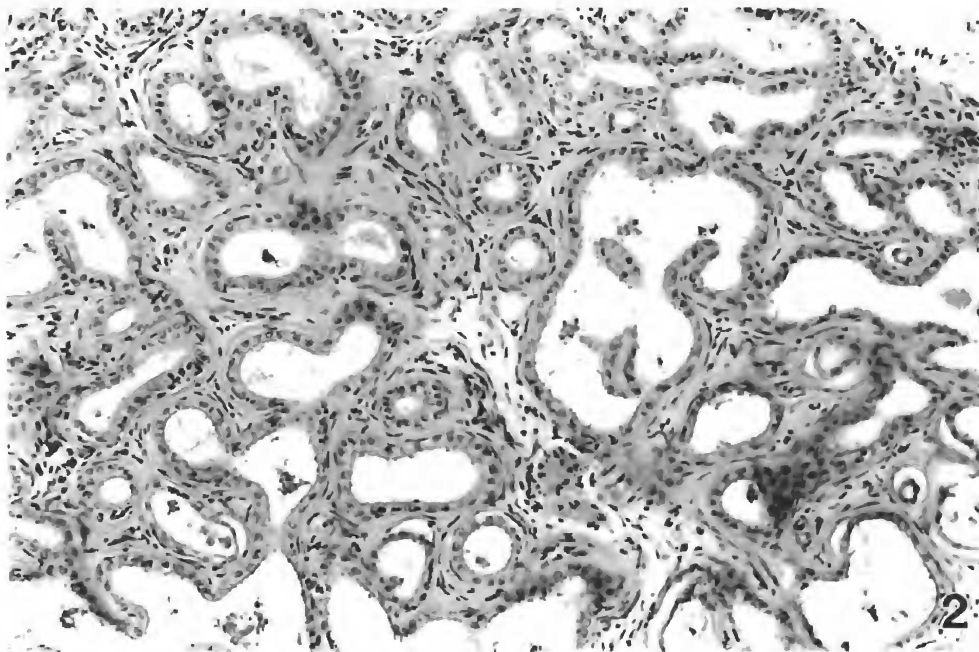


Figure 2. High power magnification of the cholangioma showing well-defined bile ducts consisting of normal-appearing cuboidal epithelium, ranging from circular to multilobular in profile and surrounded by a minimal connective tissue matrix. (H&E; 257x).

matrix of connective tissue (Figure 2). Bile duct profiles ranged from small circular configurations to relatively large multilocular structures. No mitotic figures were noted. No positive reaction with any of the P-glycoprotein antibodies tested was observed. The architecture and cellular profile of this lesion resembled that of cholangiomas described from field collections (e.g., Dawe et al. 1964; Myers et al. 1987; Bunton and Baksi 1988) and of chemically-induced cholangiomas reported from various small fish species (e.g., Hawkins et al. 1988; Grizzle and Thiagarajah 1988).

The present case is important in that it represents only the second case of a hepatic neoplasm from a wild-caught sheepshead minnow. Furthermore, this is the first report of a biliary neoplasm from this species that was not experimentally-induced or from any other wild-caught fish species in the Gulf of Mexico. Numerous specimens from wild and laboratory-reared populations of sheepshead minnows from the northern Gulf of Mexico have been used in toxicity and carcinogenicity studies with no neoplastic lesions reported from any untreated experimental specimens (see Couch and Courtney 1987) and only one neoplasm observed from a wild specimen (Oliveira et al. 1994). These observations support a very low rate of spontaneous neoplasm development in the sheepshead minnow, an important consideration in the evaluation of results of carcinogenicity tests and in field monitoring. Furthermore, Vogelbein et al. (1990) demonstrated the significance of utilizing small fish species that have a restricted home

range in monitoring for environmental carcinogens. This study showed that a few hundred meters can make a significant difference in the histology of fishes located around a point-source contamination.

Most other sheepshead minnows used at the Gulf Breeze EPA laboratory were collected at sites several kilometers west of the location where these specimens were sampled. The significance of finding one hepatic neoplasm at this site in a sample of only 10 fish histologically examined is unclear. As in the report of Oliveira et al. (1994), the present case does not constitute an epizootic, and the collection site is considered uncontaminated, with no significant commercial or residential development in its general vicinity and no other apparent sources of xenobiotic contamination. Nevertheless, this report further demonstrates the susceptibility of the sheepshead minnow to neoplastic development and supports its selection as a subject for field monitoring of carcinogenic exposure.

ACKNOWLEDGMENT

I wish to thank Dr. John Fournie for examining the slides and confirming the diagnosis. This is Contribution 932 of the U.S. Environmental Protection Agency National Health and Environmental Effects Research Laboratory, Gulf Ecology Division, Gulf Breeze, Florida (formerly the U.S. EPA Environmental Research Laboratory, Gulf Breeze).

LITERATURE CITED

- Baumann, P.C. 1992. The use of tumors in wild populations of fish to assess ecosystem health. *J Aquat Ecosys Health* 1:135-146.
- Bunton, T.E. and S.M. Baksi. 1988. Cholangioma in white perch (*Morone americana*) from the Chesapeake Bay. *J Wildl Dis* 24:137-141.
- Couch J.A. and L.A. Courtney. 1987. N-nitrosodiethylamine-induced hepatocarcinogenesis in estuarine sheepshead minnow (*Cyprinodon variegatus*): Neoplasms and related lesions compared with mammalian lesions. *J Natl Cancer Inst* 79:297-321.
- Dawe, C.J. and J.A. Couch. 1984. Debate: Mouse versus minnow: The future of fish in carcinogenicity testing. *Natl Cancer Inst Monogr* 65:223-235.
- Dawe, C.J., M.F. Stanton and P.J. Schwartz. 1964. Hepatic neoplasms in native bottom-feeding fish of Deep Creek Lake, Maryland. *Cancer Res* 24:1194-1201.
- Grizzle, J.M. and A. Thiagarajah. 1988. Diethylnitrosamine-induced hepatic neoplasms in the fish *Rivulus ocellatus marmoratus*. *Dis Aquat Org* 5:39-50.
- Harshbarger, J.C. and J.B. Clark. 1990. Epizootiology of neoplasms in bony fish of North America. *Sci Total Environ* 94:1-32.
- Hawkins, W.E., W.W. Walker, T.F. Lytle, J.S. Lytle and R.M. Overstreet. 1991. Studies on the carcinogenic effects of benzo[a]pyrene and 7,12 dimethylbenzo[a]anthracene on the sheepshead minnow (*Cyprinodon variegatus*). In: M.A. Mayes and M.G. Baron (eds.), *Aquatic Toxicology and Risk Assessment: Fourteenth Volume*. ASTM STP 1124, American Society for Testing and Materials, Philadelphia, PA. p 97-104.
- Hawkins, W.E., W.W. Walker, R.M. Overstreet, T.F. Lytle and J.S. Lytle. 1988. Dose-related carcinogenic effects of water-borne benzo[a]pyrene on livers of two small fish species. *Ecotoxicol Environ Saf* 16:219-231.
- Hemmer, M.J., L.A. Courtney and L.S. Ortego. 1995. Immunohistochemical detection of P-glycoprotein in teleost tissues using mammalian polyclonal and monoclonal antibodies. *J Exp Zool* 272:69-77.
- Lightner, D.V. and D.A. Meineke. 1979. A thyroid tumor in a sheepshead minnow (*Cyprinodon variegatus*) from the Gulf of Mexico. *Trans Am Fish Soc* 104:138-139.
- Myers, M.S., L.D. Rhodes and B.B. McCain. 1987. Pathologic anatomy and patterns of occurrence of hepatic neoplasms, putative preneoplastic lesions, and other idiopathic hepatic conditions in English sole (*Parophrys vetulus*) from Puget Sound, Washington. *J Natl Cancer Inst* 78:333-363.
- Nigrelli, R.F. 1952. Spontaneous neoplasms in fishes. VI. Thyroid tumors in marine fishes. *Zoologica* 37:185-189.
- Oliveira, M.F.T., W.E. Hawkins, R.M. Overstreet and W.W. Walker. 1994. Hepatocellular neoplasm in a wild-caught sheepshead minnow (*Cyprinodon variegatus*) from the northern Gulf of Mexico. *Gulf Res Rep* 9:65-67.
- Vogelbein, W.K., J.W. Fournie, P.A. van Veld and R.J. Huggett. 1990. Hepatic neoplasms in the mummichog *Fundulus heteroclitus* from a creosote-contaminated site. *Cancer Res* 50:5978-5989.